
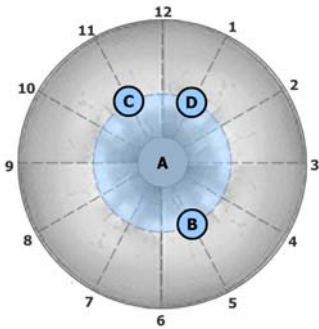


Patient Information		
Name: TESTING, ANGIE DOB (AGE) Sex: 1/1/1928 (81) F MRN (Client MRN): 000464850		
Billing #: 201142009 Order #:		
Client Information	Specimen Information	
Location: Dallas Family Prac ** Copy To: Outside Client.:	Collected Date: 9/2/2009 Accession Date: 9/2/2009 Reported Date: 9/3/2009 Submitting: 100001 - TEST ADT Doctor	Accession #: S09-389 Client Case #: Report Type: Final Report

SURGICAL PATHOLOGY DIAGNOSIS

Electronically Signed Out: Steven C. Meschter, M.D. - GMC Lab



- A. Endocervix, curetting:**
 - High grade squamous intraepithelial lesion (CIN3, severe dysplasia)
- B. Cervix, biopsy at 5 o' clock:**
 - Benign cervical mucosa with atrophy.
- C. Cervix, biopsy at 11 o' clock:**
 - Benign cervical mucosa with atrophy.
- D. Cervix, biopsy at 1 o' clock:**
 - Benign cervical mucosa with atrophy.

Clinical History

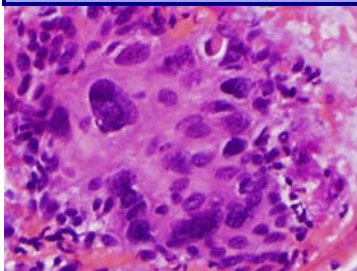
Pre-op diagnosis: HGSIL pap.

Gross Description

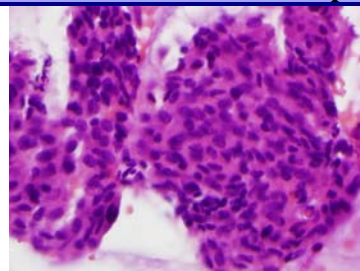
Grossed:	Grossed By: Kristin L Stiver	Gross Status:
----------	------------------------------	---------------

- A: The specimen is received in formalin labeled ECC. The specimen consists of mucus, blood and fragments of red-tan tissue that measure 0.5 x 0.5 x 0.1 cm in aggregate. The specimen is placed in a biopsy bag and entirely submitted in cassette A1.
- B: The specimen is received in formalin labeled cervix at 5 o' clock. The specimen consists of a fragment of rubbery tan-white tissue measuring 0.6 cm in greatest dimension. The specimen is placed in a biopsy bag and entirely submitted in cassette B1.
- C: The specimen is received in formalin labeled cervix at 11 o' clock. The specimen consists of a fragment of rubbery tan-white tissue measuring 0.5 cm in greatest dimension. The specimen is placed in a biopsy bag and entirely submitted in cassette C1.
- D: The specimen is received in formalin labeled cervix at 1 o' clock. The specimen consists of a fragment of rubbery tan-white tissue measuring 0.3 cm in greatest dimension. The specimen is placed in a biopsy bag and entirely submitted in cassette D1. KS

Microscopic Findings



HSIL in endocervical curetting
morphologic impression of a HSIL.



HSIL in endocervical curetting

A. Section of the endocervical curetting contains portions of endocervical glandular epithelium and mucus. There are detached fragments of dysplastic epithelium suggesting a high grade squamous intraepithelial lesion (CIN 3, severe dysplasia). There are also focal changes suggesting HPV associated cellular change. Immunocytochemical assays were performed. In the areas of high grade squamous intraepithelial lesion (HSIL) there is strong p16 positivity and numerous nuclei throughout the thickness of the epithelium are decorated with MiB-1. These findings support the

Photographic images and diagrams represent key findings in this case; they are not intended to replace a complete review of the final diagnostic report.

The following statement applies to Flow Cytometry, Immunohistochemistry, Molecular Genetics, Immunofluorescence, and In situ Hybridization Assays: This test was developed and its performance characteristics determined by Geisinger Medical Laboratories. It has not been cleared or approved by the U.S. Food and Drug Administration. The FDA has determined that such clearance or approval is not necessary. This test is used for clinical purposes. It should not be regarded as investigational or for research.

B. Sections and levels of the cervical biopsy at 5 o' clock contain fragments of cervix from the cervical/endocervical junction. There is significant atrophic change in the epithelium. There is no evidence of HPV associated cellular change or of frank dysplasia. Immunocytochemical assays were performed. The atrophic epithelium is essentially negative for p16 without any nuclear labeling with MiB-1. These findings support the morphologic impression of atrophy.

C. Sections and levels of the cervical biopsy at 11 o' clock contain fragments of cervix. The epithelium is squamous with significant atrophy. There is no evidence of HPV associated cellular change or of frank dysplasia.

D. Sections and levels of the cervical biopsy at 1 o' clock contain fragments of cervix. The epithelium is squamous. There is no evidence of HPV associated cellular change or of frank dysplasia.

CPT Code(s): A: 88305,88342IMMUNOP,88342IMMUNOP; B: 88305,88342IMMUNOP,88342IMMUNOP; C: 88305; D: 88305